

# Management of Distal Clavicle Fractures

Rahul Banerjee, MD  
 Brian Waterman, MD  
 Jeff Padalecki, MD  
 William Robertson, MD

## Abstract

Most clavicle fractures heal without difficulty. However, radiographic nonunion after distal clavicle fracture has been reported in 10% to 44% of patients. Type II distal clavicle fractures, which involve displacement, are associated with the highest incidence of nonunion. Several studies have questioned the clinical relevance of distal clavicle nonunion, however. Nonsurgical and surgical management provide similar results. The decision whether to operate may be influenced by the amount of fracture displacement and the individual demands of the patient. Surgical options to achieve bony union include transacromial wire fixation, a modified Weaver-Dunn procedure, use of a tension band, screw fixation, plating, and arthroscopy. Each technique has advantages and disadvantages; insufficient evidence exists to demonstrate that any one technique consistently provides the best results.

From the Department of Orthopaedic Surgery, University of Texas Southwestern Medical Center, Dallas, TX (Dr. Banerjee, Dr. Padalecki, and Dr. Robertson), and the Department of Orthopaedic Surgery and Rehabilitation, Texas Tech University Health Sciences Center, El Paso, TX (Dr. Waterman).

Dr. Banerjee or an immediate family member has received research or institutional support from Synthes, Smith & Nephew, Medtronic, and Stryker, and serves as a board member, owner, officer, or committee member of the American Academy of Orthopaedic Surgeons. Dr. Robertson serves as a paid consultant to ConMed Linvatec. Neither of the following authors nor any immediate family member has received anything of value from or owns stock in a commercial company or institution related directly or indirectly to the subject of this article: Dr. Waterman and Dr. Padalecki.

*J Am Acad Orthop Surg* 2011;19:392-401

Copyright 2011 by the American Academy of Orthopaedic Surgeons.

Fractures of the distal clavicle account for approximately 10% to 30% of all clavicle fractures.<sup>1</sup> Management of distal clavicle fractures is often challenging because of the difficulty in distinguishing subtle variations in the fracture pattern that may indicate fracture instability. Stable fracture patterns generally heal uneventfully with nonsurgical management, but unstable fracture patterns are often associated with longer time to union and notable nonunion rates.

Because of concern that nonsurgical management may result in nonunion, primary surgical management has been recommended for certain distal clavicle fracture patterns.<sup>2-6</sup> However, these nonunions are often asymptomatic, and their clinical relevance has been questioned.<sup>1,7</sup> The use of nonsurgical management is bolstered by the various complications that have historically been reported following surgical fixation. As a result, there is uncertainty regarding

not only which distal clavicle fractures require surgical fixation but also which fixation method is best.

## Anatomy and Biomechanics

The clavicle serves as a strut connecting the upper extremity to the appendicular skeleton. Fluid scapulohoracic motion is dependent on a stable relationship between the distal clavicle and the scapula. This stability is provided by the acromioclavicular (AC) joint capsule, AC ligaments, and coracoclavicular (CC) ligaments.

The AC ligaments span the AC joint, attaching to both the medial aspect of the acromion and the distal extent of the clavicle and reinforcing the AC joint capsule. These ligaments serve as an important stabilizer to horizontal (AP) motion at the AC joint.<sup>8</sup> This capsuloligamentous complex attaches to the distal aspect of the clavicle approximately 6 mm

medial to the AC joint.<sup>9</sup>

The CC ligaments (ie, trapezoid, conoid) originate at the base of the coracoid process of the scapula and insert on the undersurface of the distal clavicle. The trapezoid is the more lateral of the two ligaments and attaches to the distal clavicle approximately 2 cm from the AC joint.<sup>9</sup> The conoid ligament, which is located more medially, attaches to the clavicle approximately 4 cm from the AC joint. These ligaments play a pivotal role in preventing superior displacement of the distal clavicle in relation to the acromion. The normal distance between the coracoid process and the undersurface of the clavicle (ie, CC interspace) is 1.1 to 1.3 cm.<sup>10</sup>

The clavicle also serves as an important origin and site of insertion for several muscles involved in motion of the shoulder and the cervical spine, including the sternocleidomastoid, anterior deltoid, and trapezius. Depending on the fracture pattern, these muscles can create deforming forces. Neer<sup>4</sup> described four deforming forces: weight of the arm; pull of the pectoralis major, pectoralis minor, and latissimus dorsi muscles; scapular rotation; and pull of the trapezius muscle on the proximal fragment.

### Classification

Neer<sup>5,11</sup> and later, Craig,<sup>12</sup> classified distal third clavicle fractures into three types based on the relationship of the fracture line to the CC ligaments and AC joint (Figure 1). Type I fractures occur lateral to the CC ligaments but spare the AC joint. The proximal fragment is stabilized to the coracoid process by the CC ligaments and to the distal fragment by the deltotrapezial fascia. Type I fractures often are only minimally displaced because of the presence of

**Figure 1**

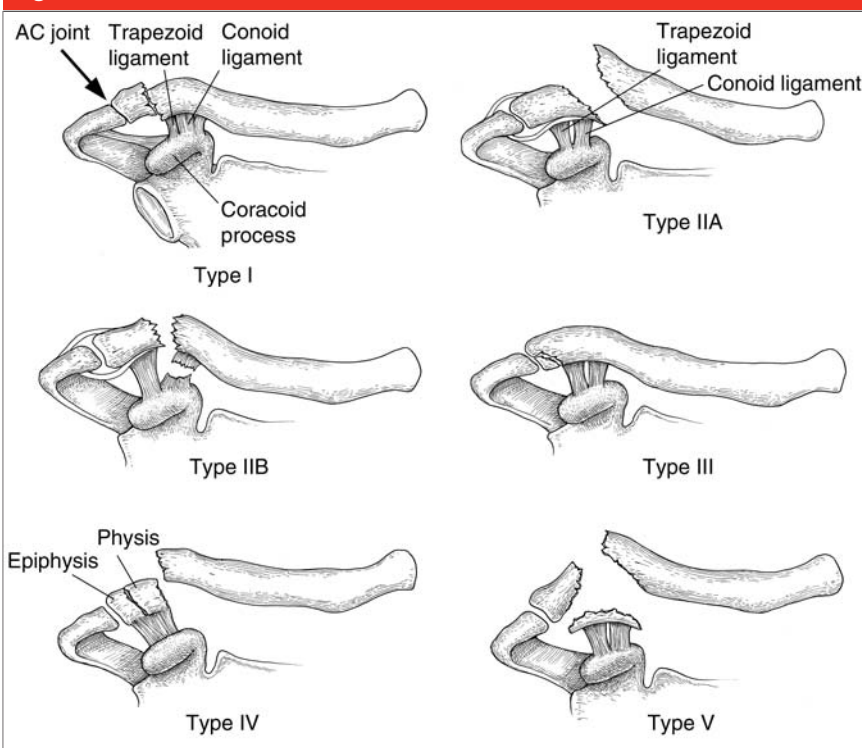


Illustration of the Neer classification of distal clavicle fractures. Type I fracture occurs distal to the coracoclavicular (CC) ligaments (ie, trapezoid, conoid) and involves minimal fracture displacement. The acromioclavicular (AC) joint remains intact. Type IIA fracture occurs medial to the conoid ligament. Type IIB fracture occurs between the CC ligaments and includes disruption of the conoid ligament. The trapezoid ligament remains intact. Type III fracture occurs distal to the CC ligaments and extends into the AC joint. Type IV fracture occurs in pediatric patients. The physis and epiphysis remain adjacent to the AC joint, but there is displacement at the junction of the metaphysis and physis. In type V fracture, a small inferior clavicular fragment remains attached to the CC ligaments.

these soft-tissue attachments.

Type III fractures are similar to type I fractures in that they also occur distal to the CC ligaments. However, type III fracture extends into the AC joint. Because the ligamentous structures remain intact, type III fractures are relatively stable and typically are minimally displaced. Persons with this injury may be at risk of posttraumatic AC joint arthropathy because of the intra-articular involvement.

Type II fractures are less stable than type I and III fractures, and they present a treatment challenge. In all type II fractures, the proximal

fragment is detached from the CC ligaments. The distal fragment remains attached to the scapula via the AC joint capsule. In type IIA fracture, the fracture lies medial to the conoid ligament. In type IIB fracture, the fracture lies between the conoid and trapezoid ligaments. The relationship of the distal fragment to the coracoid process may differ between types IIA and IIB.

In type IIA fractures, the distal fragment remains connected to the coracoid process by the CC ligaments, which are presumed to be intact. With type IIB fractures, the CC ligaments lie within the zone of in-

Figure 2

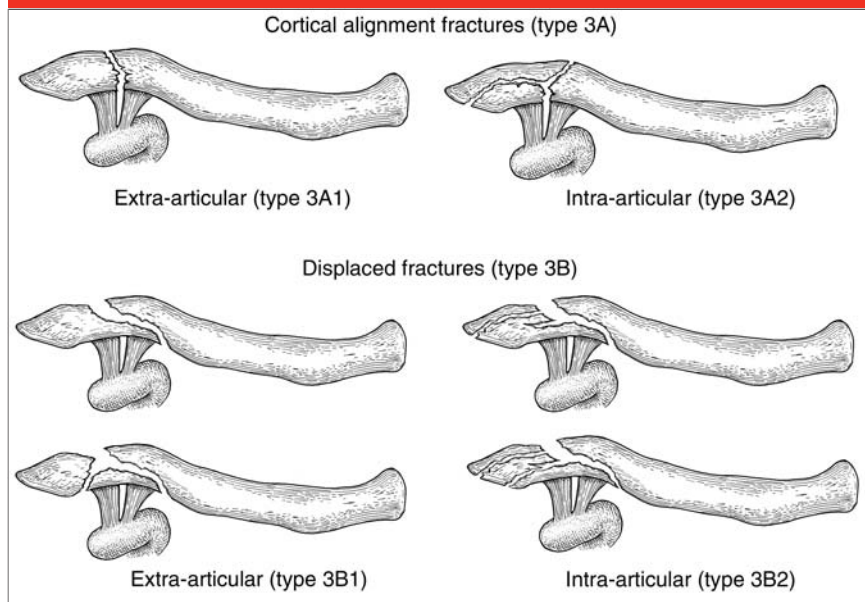


Illustration of the Robinson classification of distal clavicle fractures (type 3). Type A, cortical alignment fractures: 1, extra-articular; 2, intra-articular. Type B, displaced fractures: 1, extra-articular; 2, intra-articular. (Redrawn with permission from Robinson CM: Fractures of the clavicle in the adult: Epidemiology and classification. *J Bone Joint Surg Br* 1998;80[3]:476-484.)

jury. In Neer type IIB fractures, the conoid ligament is torn, but the trapezoid is presumed to remain attached to the distal fragment.<sup>12</sup> This classification was developed before widespread use of MRI, and we are unaware of any study that has confirmed the integrity of the trapezoid and conoid ligaments in type IIA and IIB injuries. Although in type II fractures, fracture displacement may be obvious, the exact location of the fracture and the integrity of the CC ligaments may be difficult to judge on plain radiographs.

Type IV and V fractures were subsequently added to the classification.<sup>11</sup> Type IV fractures are rare; they involve disruption of the periosteal sleeve in the pediatric population.<sup>13,14</sup> These fractures are injuries to the growth plate in which the epiphysis and physis typically maintain their relationship to the shoulder joint, resulting in apparent superior displacement of the clavicular me-

taphysis. Depending on the degree of displacement, these patients are treated with closed or open reduction.<sup>14</sup> In type V fracture, only a small inferior cortical fragment remains attached to the CC ligaments. Type V fractures are functionally similar to type II injuries in that neither the proximal nor the distal fragment is connected to the coracoid process via the CC ligaments. Although the ligaments may remain attached to a free-floating bony fragment, the stability of the distal and proximal fracture fragments is compromised. Although the Craig modification of the Neer classification system is widely used, no study has assessed the validity of this classification through inter- and intraobserver reliability.

Robinson<sup>15</sup> proposed an alternative classification for all clavicle fractures based on fracture location, displacement, and intra-articular involvement (Figure 2). Distal clavicle frac-

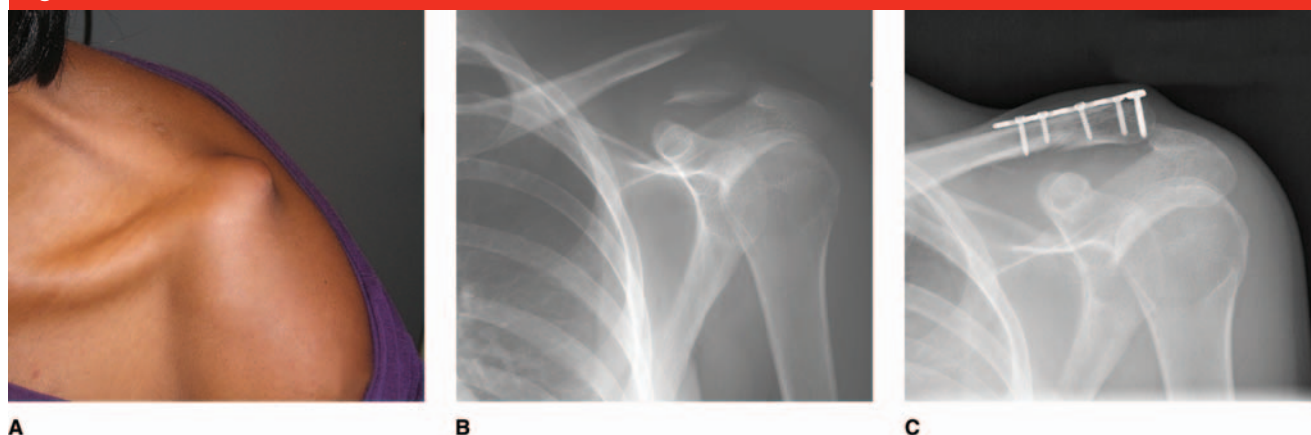
tures were classified as type 3. These occur lateral to a vertical line drawn upward from the center of the coracoid process. Robinson grouped fractures into subgroups A and B based on displacement of the major fragments. Subtypes A and B were subdivided according to articular involvement. This classification was found to have substantial interobserver reliability (mean kappa value = 0.77) and excellent intraobserver reliability (average kappa value = 0.84).

### Clinical Evaluation

Most distal clavicle fractures are the result of a fall onto the distal clavicle or a direct blow to it.<sup>1,16</sup> Direct impact occurs at the acromion, usually with the arm in an adducted position, and force is transmitted through the AC joint to the CC ligaments and the distal clavicle. Patients with distal clavicle fractures typically present with shoulder pain. Associated injuries should be ruled out, such as other injuries to the shoulder girdle, rib fracture, ipsilateral upper extremity injury, and injury to the thorax or cervical spine. These are particularly likely to occur in conjunction with high-energy mechanisms.

Physical examination findings include swelling, ecchymosis, and tenderness over the distal clavicle, as well as painful active and passive range of motion (ROM) of the shoulder. Fracture displacement may cause the proximal fragment to tent the skin, with an appearance similar to that of AC joint separation (Figure 3). Paresthesias resulting from swelling or injury to the supraclavicular nerves are common. Neurologic examination of the shoulder and upper extremity should be performed and documented. Suprascapular nerve injury after distal clavicle fracture has been described.<sup>17</sup> Weakness on external rotation with the arm in

Figure 3



**A**, Clinical photograph of a displaced left distal clavicle fracture in a 21-year-old woman who fell onto her left shoulder. **B**, Preoperative AP radiograph demonstrating fracture displacement with no residual cortical contact between the bone ends. The patient was treated with a distal radius 2.4-mm locking plate and simultaneous coracoclavicular stabilization using suture. **C**, AP radiograph obtained 3 months postoperatively demonstrating fracture healing.

adduction and disproportionate reports of pain could be indicative of suprascapular nerve injury. Careful examination of the remainder of the upper extremity, as well as the cervical spine and the thorax, is essential.

### Radiographic Evaluation

Radiographic evaluation should include true AP and axillary lateral views of the shoulder. A Zanca view of the AC joint, which is obtained in 10° to 15° cephalic tilt, is also helpful in evaluating for intra-articular involvement.<sup>18</sup> A radiograph showing the bilateral clavicles and including the AC joint is useful in assessing fracture displacement. These radiographs can provide an overall assessment of fracture pattern, location, and displacement.

### Management

Distal clavicle fractures may be managed nonsurgically or surgically. Most nondisplaced distal clavicle fractures are managed nonsurgically. For example, Neer type I and III dis-

tal clavicle fractures are typically nondisplaced and heal without difficulty with nonsurgical management. In contrast, type II fractures are often displaced and may have a higher rate of nonunion.<sup>4</sup> Reported rates of nonunion following nonsurgical management of type II distal clavicle fractures range from 28% to 44%<sup>1,4,5,7,11,19-21</sup> (Table 1). Most studies define distal clavicle fracture nonunion based on Neer's original series. Neer defined delayed nonunion as "lack of bone bridging for more than 12 months after injury."<sup>4</sup> This definition has been used in subsequent studies on distal clavicle fracture.

Deafenbaugh et al<sup>21</sup> reported 3 nonunions in a series of 10 Neer type II distal clavicle fractures. Nordqvist et al<sup>20</sup> reported a 28% nonunion rate (5 of 18). In their review of 43 type II distal clavicle fractures, Edwards et al<sup>22</sup> noted that up to 75% of patients treated nonsurgically developed a delayed union or nonunion. Of the 20 patients treated nonsurgically, 6 (30%) developed nonunion (ie, lack of bony bridging after 12 months). The authors of these three

series used the Neer definition of nonunion. Rokito et al<sup>7</sup> reported nonunion in 7 of 16 patients treated nonsurgically for type II distal clavicle fractures.

Risk factors for nonunion include displacement, that is, no residual cortical contact between the bone ends, and advancing patient age.<sup>19</sup> Robinson et al<sup>19</sup> noted that both of these factors are independently predictive of nonunion.

Because some patients remain asymptomatic, the clinical importance of distal clavicle nonunion has been questioned. In the study by Deafenbaugh et al,<sup>21</sup> none of the three reported distal clavicle nonunions was symptomatic. Other studies involving clinical assessment of patients with distal clavicular nonunions have indicated that 20% to 34% were symptomatic and eventually required surgical fixation.<sup>1,20</sup>

Closer evaluation of studies that included outcomes scores in their analyses further clarifies the impact of distal clavicle nonunion. In the small series by Rokito et al,<sup>7</sup> 7 of the 16 patients treated nonsurgically de-

**Table 1****Reported Rates of Nonunion Following Nonsurgical Management of Type II Distal Clavicle Fractures**

Study	Level of Evidence	Total No. of Pts	No. of Pts With Neer Type II Fracture	No. of Pts Followed to End of Study
Neer <sup>4</sup>	IV (case series)	23	23	23
Deafenbaugh et al <sup>21</sup>	II (prospective study)	10	10	10
Edwards et al <sup>22</sup>	IV (case series)	43	43	43 <sup>c</sup>
Nordqvist et al <sup>20</sup>	IV (case series)	110	23	18 <sup>d</sup>
Rokito et al <sup>7</sup>	IV (case series)	30	30	30
Robinson and Cairns <sup>1</sup>	IV (case series)	101	90	86 <sup>e</sup>
Robinson et al <sup>19</sup>	I (prospective study)	263	99	84 <sup>g</sup>

N/A = not applicable, NR = not reported, ORIF = open reduction and internal fixation, Pts = patients

<sup>a</sup> In the nonsurgical group, no fracture was "united by callus prior to 16 weeks after injury."

<sup>b</sup> In the surgical group, "[h]eavy labor was resumed at the third month."

<sup>c</sup> Only 38 patients were reviewed clinically and radiographically. The authors state, "[T]he remaining 5 had adequate case notes and radiographs."

<sup>d</sup> Only 18 of the 23 patients with Neer type II distal clavicle fractures were evaluated radiographically at final follow-up.

<sup>e</sup> 86 of the original 101 patients were available for follow-up, but the authors do not specify how many of these were Neer type II clavicle fractures.

<sup>f</sup> This rate is based on all 86 lateral or distal clavicle fractures; the authors do not specify Neer classification.

<sup>g</sup> 84 lateral end clavicle fractures were followed for 24 weeks. Although 42 fractures were displaced, the number of Neer type II fractures was not reported.

<sup>h</sup> The authors report a 25.4% nonunion rate for displaced lateral end clavicle fractures but an overall nonunion rate of 11.5% (ie, displaced and nondisplaced).

veloped nonunion, but there was no difference in mean Constant or American Shoulder and Elbow Surgeons (ASES) scores between those treated nonsurgically and those treated surgically. In the case series by Robinson and Cairns,<sup>1</sup> there was no significant difference in the Constant score or the Medical Outcomes Study 36-Item Short Form score between any of the three groups studied: patients treated nonsurgically, patients who developed a nonunion, and patients who underwent delayed surgical treatment after the development of a nonunion.

Based on these data, several conclusions may be reached regarding nonunion after distal clavicle fracture: (1) The reported rate of radiographic nonunion of all types of dis-

tal clavicle fractures reflects that of Neer's original series. (2) Fracture displacement, as seen in most Neer type II fractures, is associated with the development of nonunion. (3) Radiographic nonunion does not always correlate with symptomatic nonunion. (4) Patients who develop symptomatic nonunion may or may not require additional surgery.

Surgical management of distal clavicle fractures is indicated for open fractures, skin compromise, and associated vascular injury requiring surgery. Because of the high rate of nonunion, Neer<sup>4</sup> and others<sup>2,3,6,23-45</sup> have advocated primary surgical management of distal clavicle fracture. However, because radiographic nonunion does not correlate with symptomatic nonunion,

management of closed displaced type II distal clavicle fracture must be approached on a case-by-case basis.

### Nonsurgical

Most distal clavicle fractures are managed nonsurgically. Sling immobilization for 2 weeks is instituted for comfort, and shoulder motion is initiated as soon as the initial pain improves. Repeat radiographs are obtained at 6-week follow-up to monitor for fracture displacement and evidence of healing. These patients typically recover fully without sequelae. Type I and type III fractures are at risk of delayed-onset symptomatic AC arthrosis,<sup>5</sup> which can be managed with distal clavicle resection, if necessary. Nondisplaced

**Table 1 (continued)****Reported Rates of Nonunion Following Nonsurgical Management of Type II Distal Clavicle Fractures**

Management	Average Follow-up	Outcome	No. of Symptomatic Nonunions
12 nonsurgical	4 mo <sup>a</sup>	8 delayed union (67%), 4 nonunion (33%)	4
4 excision	NR	N/A	NR
7 ORIF	3 mo <sup>b</sup>	All united	0
Nonsurgical	14.3 mo	3 nonunion (30%)	0
20 nonsurgical	3 y	9 delayed union (45%), 6 nonunion (30%)	6
23 surgical	21 mo	All united	0
Nonsurgical	15 y	5/18 nonunion (28%)	2
16 nonsurgical	53.5 mo	7 nonunion (44%)	2
14 ORIF	59.8 mo	All united	0
72 nonsurgical, 3 excision, 11 delayed surgery	6.2 y	32/86 nonunion (37%) <sup>f</sup>	11
Nonsurgical	24 wk	25.4% nonunion <sup>h</sup>	NR

N/A = not applicable, NR = not reported, ORIF = open reduction and internal fixation, Pts = patients

<sup>a</sup> In the nonsurgical group, no fracture was "united by callus prior to 16 weeks after injury."

<sup>b</sup> In the surgical group, "[h]eavy labor was resumed at the third month."

<sup>c</sup> Only 38 patients were reviewed clinically and radiographically. The authors state, "[T]he remaining 5 had adequate case notes and radiographs."

<sup>d</sup> Only 18 of the 23 patients with Neer type II distal clavicle fractures were evaluated radiographically at final follow-up.

<sup>e</sup> 86 of the original 101 patients were available for follow-up, but the authors do not specify how many of these were Neer type II clavicle fractures.

<sup>f</sup> This rate is based on all 86 lateral or distal clavicle fractures; the authors do not specify Neer classification.

<sup>g</sup> 84 lateral end clavicle fractures were followed for 24 weeks. Although 42 fractures were displaced, the number of Neer type II fractures was not reported.

<sup>h</sup> The authors report a 25.4% nonunion rate for displaced lateral end clavicle fractures but an overall nonunion rate of 11.5% (ie, displaced and nondisplaced).

type II fractures may also be managed nonsurgically. However, the likelihood of subsequent displacement and possible nonunion should be recognized, discussed with the patient, and monitored with repeat radiographs at 6 weeks.

### Surgical

A variety of methods of surgical management of distal clavicle fractures has been proposed, including transacromial wire fixation, a modified Weaver-Dunn procedure, use of a tension band, CC screw fixation, plate fixation, and arthroscopic treatment. Neer<sup>4</sup> recommended transacromial wire fixation of distal clavicle fractures. This commonly used technique has been associated with a high rate of complica-

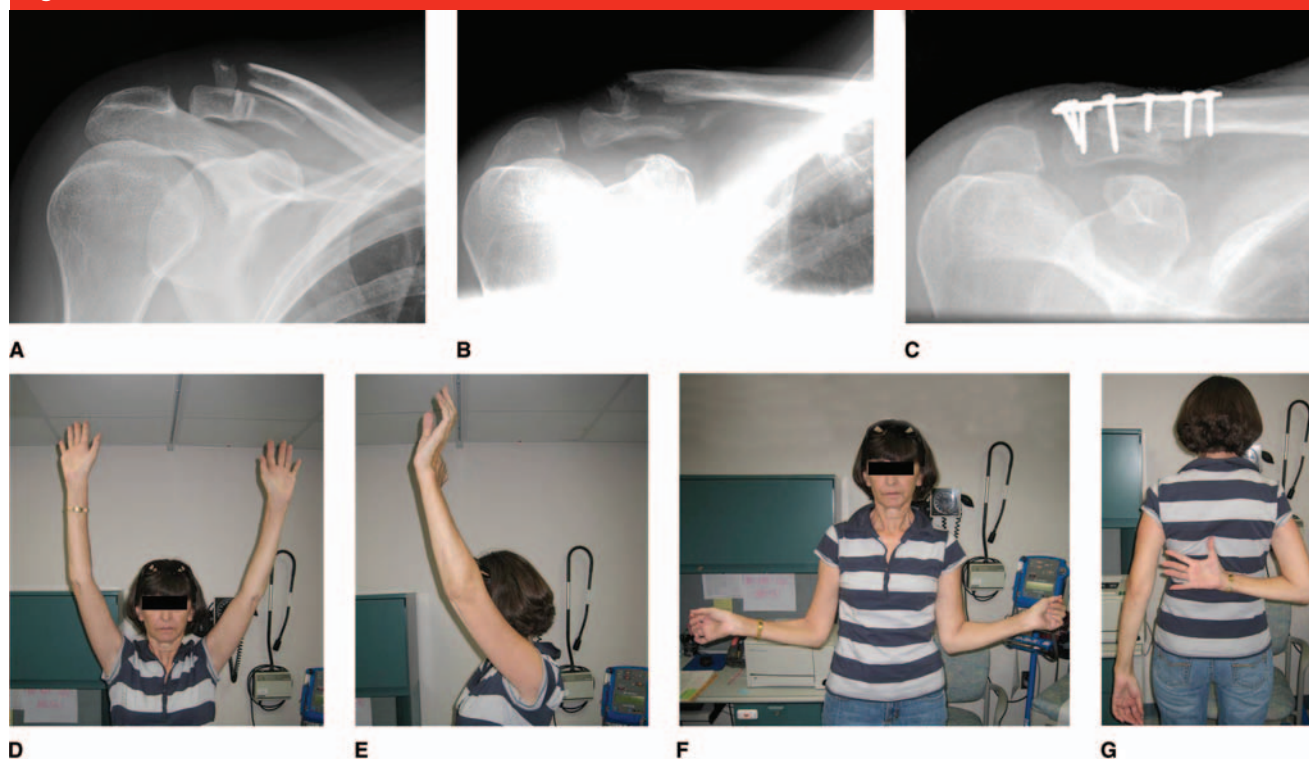
tions, including nonunion, AC arthrosis, and Kirschner wire (K-wire) migration. Although Eskola et al<sup>46</sup> reported good or satisfactory outcomes in 22 of 23 patients, 26% experienced a complication or nonunion following transacromial wiring. Late migration of the wires into the cervical spine, trachea, vascular structures, lung, and abdomen has been reported.<sup>47-49</sup> Modifications have led to a reduction in unsatisfactory results and complications associated with transacromial wire fixation. Good results have been reported with the use of a transacromial Knowles pin rather than K-wires.<sup>23,24</sup> Transacromial fixation supplemented with CC ligament repair or reconstruction has also been shown to improve results and

decrease complications.<sup>24-26</sup>

CC ligament repair or reconstruction without supplemental fixation has been reported.<sup>6,27</sup> Webber and Haines<sup>6</sup> described CC ligament reconstruction using a Dacron graft in 11 patients. All fractures united by an average of 43.5 days postoperatively. At a mean follow-up of 4.6 years, the average Constant score was 98.9.

The modified Weaver-Dunn procedure is primarily used for AC dislocation, but it also has been advocated for the management of distal clavicle fractures.<sup>50</sup> This procedure is usually reserved for cases in which the distal clavicle fragment can be easily excised and the coracoacromial ligament can be transferred to the distal end of the proximal

Figure 4



**A**, AP radiograph of the right shoulder in a 56-year-old woman who sustained a closed distal clavicle fracture after a fall. **B**, The patient was initially treated nonsurgically and developed painful nonunion. She then underwent fixation with a 2.7-mm plate, which allowed placement of three screws into the distal fragment. The fixation was augmented with coracoclavicular stabilization using Mersilene tape. AP radiograph (**C**) and postoperative photographs (**D** through **G**) obtained 3 months postoperatively demonstrating healing and return to preinjury level of function.

clavicle fragment.

K-wire fixation with a supplementary tension band wire has also been suggested for fixation of type II distal clavicle fractures.<sup>51</sup> In this method, K-wires are placed on the superior aspect of the clavicle, avoiding the AC joint. The tension band is placed around the wires. In one series, 11 of 12 patients achieved painless union with this approach.<sup>52</sup> Others have reported similar success rates with modified tension band techniques using suture.<sup>28-30</sup> Symptomatic hardware is a potential complication, particularly when tension band wiring is used.<sup>31</sup>

In CC screw fixation, open reduction and internal fixation of the distal clavicle fragment is performed by temporarily fixing the distal clavicle

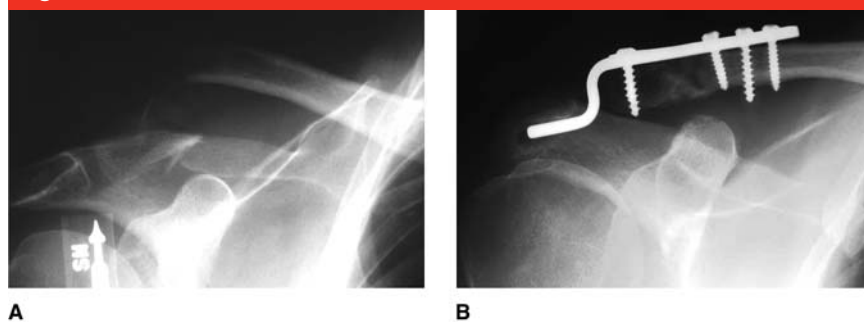
to the coracoid process. Successful healing of the distal clavicle has been reported in several small case series.<sup>22,32-34</sup> This technique has also been performed using a cannulated screw.<sup>35</sup> More recently, Fazal et al<sup>36</sup> reported a 100% union rate using this technique in 30 patients. A second procedure is required to remove the screw following union.

Small and mini-fragment locking plates may be used to stabilize distal clavicle fractures (Figures 3 and 4). These plates allow fixation of the distal clavicle fragment without crossing the AC joint. Kalamaras et al<sup>37</sup> used a distal radius locking plate on nine patients with distal clavicle fracture. The 2.4-mm locking screws in the distal portion of the plate were used to capture the distal

clavicle fragment. All eight patients who were available for follow-up achieved bony union. The mean Constant score was 96.

If the distal fragment is too small to hold screws, a plate that hooks under the acromion may be used (Figure 5). Kashii et al<sup>38</sup> reported on 34 patients with distal clavicle fractures treated with an AC hook plate. Although all patients achieved bony union, the hook caused acromial fracture in one patient and rotator cuff tear in another. Good union rates with the hook plate were reported in two other studies, but asymptomatic osteolysis of the acromion and migration of the hook into the acromion were frequently encountered.<sup>39,40</sup> With the hook plate, a second procedure is required for

Figure 5



**A**, AP radiograph of the right shoulder in a 60-year-old man who sustained a displaced distal clavicle fracture in a fall. He was treated with open reduction and internal fixation using a distal clavicle hook plate. **B**, AP radiograph obtained 5 months postoperatively demonstrating fracture healing. The plate was removed 9 months postoperatively.

plate removal, which may cause additional morbidity.

Plate fixation may be supplemented with CC screw fixation through the plate or with CC ligament repair or reconstruction. Supplemental CC fixation may also be achieved with sutures or suture anchors. Recently, Herrmann et al<sup>3</sup> described the use of a locking T-plate in addition to suture anchors placed into the coracoid in eight patients. The sutures were placed around the clavicle and over the plate. Bony union was achieved in 6 weeks in the seven patients who were available for follow-up; the mean Constant score was 93.3.

Arthroscopic techniques for the management of distal clavicle fractures have also been reported. These techniques employ some of the same strategies used in arthroscopically assisted CC ligament reconstruction following AC joint separation. Published reports are limited to small case series and technical notes, and all involve arthroscopic CC stabilization using suture, a double-button device, or the Tightrope system (Arthrex, Naples, FL).<sup>41-44</sup>

Only two studies to date have directly compared two methods of surgical management. Flinkkilä et al<sup>45</sup>

retrospectively compared K-wire fixation with the use of a clavicular hook plate (22 and 17 patients, respectively). Although both methods restored shoulder function, K-wire fixation was associated with wire migration in 12 patients, loss of reduction in 7, infection in 3, and nonunion in 2. In the group treated with clavicle hook plates, one patient sustained a clavicle fracture, and two fractures went on to nonunion. More recently, Lee et al<sup>31</sup> retrospectively reviewed patients treated with either clavicular hook plates or tension-band wiring (32 and 20 patients, respectively). Hook plating was associated with a lower complication rate and a lower rate of symptomatic hardware. In addition, it better facilitated return to work and athletic activity.

### Authors' Preferred Management

We recommend primary nonsurgical management of type I, type III, and nondisplaced type II distal clavicle fractures. Patients are treated with sling immobilization for 2 weeks. During this period, supine passive ROM and active-assisted ROM are

initiated. When pain has improved and there are early signs of fracture consolidation, active ROM is allowed.

For the patient with displaced type II distal clavicle fracture or displaced type IV or V fracture, treatment selection is based on the degree of displacement and a discussion with the patient. Robinson et al<sup>19</sup> defined displacement (ie, no residual cortical contact between the bone ends) as a risk factor for nonunion. For patients with displacement, we offer surgical treatment but counsel them that the current evidence suggests equivalent outcomes between surgical and nonsurgical treatment.

Our preferred surgical management technique is internal fixation of the distal clavicle fracture with supplementary CC fixation (Figures 3 and 4). If the distal clavicle fragment is large enough to hold screws, we use a small, low-profile locking plate and perform open anatomic fracture reduction. The coracoid process is identified to allow for suture passage. The fixation is supplemented by CC stabilization, which is achieved with sutures placed around the coracoid process and either around or through a small hole in the clavicle, proximal to the fracture.

For cases in which the size or quality of the distal fracture fragment is insufficient for plate application, we recommend CC stabilization using nonabsorbable suture such as Ethibond (Ethicon, Somerville, NJ), FiberWire (Arthrex, Naples, FL), or Mersilene (Ethicon). This approach requires exposure of the coracoid process. Two strands of suture are passed around the coracoid process. The ends of the suture are then passed through a small drill hole in the proximal clavicle fragment. The distal clavicle is reduced, and the first suture is tied. Once reduction is confirmed visually and radiographically, the second suture is tied. The



fixation is supplemented by a dorsal suture tension band placed through the incision, as described by Levy.<sup>30</sup> Surgeons who are trained in shoulder arthroscopy may perform the procedure arthroscopically.

Postoperatively, the patient is placed in a sling for 6 weeks. Supine passive and active-assisted ROM exercises are begun immediately. Active ROM is started at 6 weeks, with progression to strengthening exercises 6 to 12 weeks postoperatively. Patients are typically restricted from engaging in heavy labor and sports for 12 weeks.

## Summary

Most distal clavicle fractures may be managed nonsurgically. Type II distal clavicle fractures are associated with radiographic nonunion in up to 44% of cases. Fracture displacement is associated with a higher risk of nonunion. However, the clinical relevance of this nonunion may be minimal, and initial nonsurgical management may be warranted. Although surgical management of distal clavicle fractures has been described, current evidence suggests equivalent outcomes between surgical and nonsurgical management. Additionally, no single surgical technique has been shown to be superior to the others. A prospective randomized study comparing surgical and nonsurgical management of type II distal clavicle fractures is necessary to better determine the optimal treatment.

## References

*Evidence-based Medicine:* Levels of evidence are listed in the table of contents. In this article, reference 19 is a level I study. Reference 21 is a level II study. References 31 and 45 are level III studies. References 1-7, 13, 14,

16, 20, 22-30, 32-40, 43, 44, and 52 are level IV studies. Reference 10 is level V expert opinion.

References printed in **bold type** indicate those published within the past 5 years.

- Robinson CM, Cairns DA: Primary nonoperative treatment of displaced lateral fractures of the clavicle. *J Bone Joint Surg Am* 2004;86(4):778-782.
- Hessmann M, Kirchner R, Baumgaertel F, Gehling H, Gotzen L: Treatment of unstable distal clavicular fractures with and without lesions of the acromioclavicular joint. *Injury* 1996;27(1):47-52.
- Herrmann S, Schmidmaier G, Greiner S: Stabilisation of vertical unstable distal clavicular fractures (Neer 2b) using locking T-plates and suture anchors. *Injury* 2009;40(3):236-239.**
- Neer CS II: Fracture of the distal clavicle with detachment of the coracoclavicular ligaments in adults. *J Trauma* 1963;3:99-110.
- Neer CS II: Fractures of the distal third of the clavicle. *Clin Orthop Relat Res* 1968;58:43-50.
- Webber MC, Haines JF: The treatment of lateral clavicle fractures. *Injury* 2000; 31(3):175-179.
- Rokito AS, Zuckerman JD, Shaari JM, Eisenberg DP, Cuomo F, Gallagher MA: A comparison of nonoperative and operative treatment of type II distal clavicle fractures. *Bull Hosp Jt Dis* 2002-2003;61(1-2):32-39.
- Fukuda K, Craig EV, An KN, Cofield RH, Chao EY: Biomechanical study of the ligamentous system of the acromioclavicular joint. *J Bone Joint Surg Am* 1986;68(3):434-440.
- Renfree KJ, Riley MK, Wheeler D, Hentz JG, Wright TW: Ligamentous anatomy of the distal clavicle. *J Shoulder Elbow Surg* 2003;12(4):355-359.
- Bearden JM, Hughston JC, Whatley GS: Acromioclavicular dislocation: Method of treatment. *J Sports Med* 1973;1(4):5-17.
- Neer C II: Fractures and dislocations of the shoulder, in Rockwood CA Jr, Green DP, eds: *Fractures in Adults*. Philadelphia, PA, J.B. Lippincott, 1984, pp 711-712.
- Craig EV: Fractures of the clavicle, in Rockwood CA Jr, Green DP, Bucholz RW, Heckman JD, eds: *Rockwood and Green's Fractures in Adults*, ed 4. Philadelphia, PA, Lippincott-Raven, 1996, pp 1109-1193.
- Katznelson A, Nerubay J, Oliver S: Dynamic fixation of the avulsed clavicle. *J Trauma* 1976;16(10):841-844.
- Ogden JA: Distal clavicular physal injury. *Clin Orthop Relat Res* 1984; (188):68-73.
- Robinson CM: Fractures of the clavicle in the adult: Epidemiology and classification. *J Bone Joint Surg Br* 1998; 80(3):476-484.
- Stanley D, Trowbridge EA, Norris SH: The mechanism of clavicular fracture: A clinical and biomechanical analysis. *J Bone Joint Surg Br* 1988;70(3):461-464.
- Huang KC, Tu YK, Huang TJ, Hsu RW: Suprascapular neuropathy complicating a Neer type I distal clavicular fracture: A case report. *J Orthop Trauma* 2005; 19(5):343-345.
- Zanca P: Shoulder pain: Involvement of the acromioclavicular joint: Analysis of 1,000 cases. *Am J Roentgenol Radium Ther Nucl Med* 1971;112(3):493-506.
- Robinson CM, Court-Brown CM, McQueen MM, Wakefield AE: Estimating the risk of nonunion following nonoperative treatment of a clavicular fracture. *J Bone Joint Surg Am* 2004;86(7):1359-1365.
- Nordqvist A, Petersson C, Redlund-Johnell I: The natural course of lateral clavicle fracture: 15 (11-21) year follow-up of 110 cases. *Acta Orthop Scand* 1993;64(1):87-91.
- Deafenbaugh MK, Dugdale TW, Staeheli JW, Nielsen R: Nonoperative treatment of Neer type II distal clavicle fractures: A prospective study. *Contemp Orthop* 1990;20(4):405-413.
- Edwards DJ, Kavanagh TG, Flannery MC: Fractures of the distal clavicle: A case for fixation. *Injury* 1992;23(1):44-46.
- Fann CY, Chiu FY, Chuang TY, Chen CM, Chen TH: Transacromial Knowles pin in the treatment of Neer type 2 distal clavicle fractures: A prospective evaluation of 32 cases. *J Trauma* 2004; 56(5):1102-1105.
- Wang SJ, Wong CS: Extra-articular knowles pin fixation for unstable distal clavicle fractures. *J Trauma* 2008;64(6): 1522-1527.**
- Bezer M, Aydin N, Guven O: The treatment of distal clavicle fractures with coracoclavicular ligament disruption: A report of 10 cases. *J Orthop Trauma* 2005;19(8):524-528.
- Chen CH, Chen WJ, Shih CH: Surgical treatment for distal clavicle fracture with coracoclavicular ligament disruption. *J Trauma* 2002;52(1):72-78.

27. Goldberg JA, Bruce WJ, Sonnabend DH, Walsh WR: Type 2 fractures of the distal clavicle: A new surgical technique. *J Shoulder Elbow Surg* 1997;6(4):380-382.
28. Mall JW, Jacobi CA, Philipp AW, Peter FJ: Surgical treatment of fractures of the distal clavicle with polydioxanone suture tension band wiring: An alternative osteosynthesis. *J Orthop Sci* 2002;7(5): 535-537.
29. Badhe SP, Lawrence TM, Clark DI: Tension band suturing for the treatment of displaced type 2 lateral end clavicle fractures. *Arch Orthop Trauma Surg* 2007;127(1):25-28.
30. Levy O: Simple, minimally invasive surgical technique for treatment of type 2 fractures of the distal clavicle. *J Shoulder Elbow Surg* 2003;12(1):24-28.
31. Lee YS, Lau MJ, Tseng YC, Chen WC, Kao HY, Wei JD: Comparison of the efficacy of hook plate versus tension band wire in the treatment of unstable fractures of the distal clavicle. *Int Orthop* 2009;33(5):1401-1405.
32. Ballmer FT, Gerber C: Coracoclavicular screw fixation for unstable fractures of the distal clavicle: A report of five cases. *J Bone Joint Surg Br* 1991;73(2):291-294.
33. Yamaguchi H, Arakawa H, Kobayashi M: Results of the Bosworth method for unstable fractures of the distal clavicle. *Int Orthop* 1998;22(6):366-368.
34. Macheras G, Kateros KT, Savvidou OD, Sofianos J, Fawzy EA, Papagelopoulos PJ: Coracoclavicular screw fixation for unstable distal clavicle fractures. *Orthopedics* 2005;28(7):693-696.
35. Jin CZ, Kim HK, Min BH: Surgical treatment for distal clavicle fracture associated with coracoclavicular ligament rupture using a cannulated screw fixation technique. *J Trauma* 2006;60(6):1358-1361.
36. Fazal MA, Saksena J, Haddad FS: Temporary coracoclavicular screw fixation for displaced distal clavicle fractures. *J Orthop Surg (Hong Kong)* 2007;15(1):9-11.
37. Kalamaras M, Cutbush K, Robinson M: A method for internal fixation of unstable distal clavicle fractures: Early observations using a new technique. *J Shoulder Elbow Surg* 2008;17(1):60-62.
38. Kashii M, Inui H, Yamamoto K: Surgical treatment of distal clavicle fractures using the clavicular hook plate. *Clin Orthop Relat Res* 2006;447:158-164.
39. Tambe AD, Motkur P, Qamar A, Drew S, Turner SM: Fractures of the distal third of the clavicle treated by hook plating. *Int Orthop* 2006;30(1):7-10.
40. Muramatsu K, Shigetomi M, Matsunaga T, Murata Y, Taguchi T: Use of the AO hook-plate for treatment of unstable fractures of the distal clavicle. *Arch Orthop Trauma Surg* 2007;127(3):191-194.
41. Nourissat G, Kakuda C, Dumontier C, Sautet A, Doursounian L: Arthroscopic stabilization of Neer type 2 fracture of the distal part of the clavicle. *Arthroscopy* 2007;23(6):674.e1-4.
42. Baumgarten KM: Arthroscopic fixation of a type II-variant, unstable distal clavicle fracture. *Orthopedics* 2008; 31(12):pii:orthosupersite.com/view.asp?rID=32937.
43. Checchia SL, Doneux PS, Miyazaki AN, Fregoneze M, Silva LA: Treatment of distal clavicle fractures using an arthroscopic technique. *J Shoulder Elbow Surg* 2008;17(3):395-398.
44. Pujol N, Philippeau JM, Richou J, Lespagnol F, Gravelleau N, Hardy P: Arthroscopic treatment of distal clavicle fractures: A technical note. *Knee Surg Sports Traumatol Arthrosc* 2008;16(9): 884-886.
45. Flinkkilä T, Ristiniemi J, Hyvönen P, Hämäläinen M: Surgical treatment of unstable fractures of the distal clavicle: A comparative study of Kirschner wire and clavicular hook plate fixation. *Acta Orthop Scand* 2002;73(1):50-53.
46. Eskola A, Vainionpää S, Päätiälä H, Rokkanen P: Outcome of operative treatment in fresh lateral clavicular fracture. *Ann Chir Gynaecol* 1987;76(3): 167-169.
47. Regel JP, Pospiech J, Aalders TA, Ruchholtz S: Intraspinal migration of a Kirschner wire 3 months after clavicular fracture fixation. *Neurosurg Rev* 2002; 25(1-2):110-112.
48. Tsai CH, Hsu HC, Huan CY, Chen HT, Fong YC: Late migration of threaded wire (schanz screw) from right distal clavicle to the cervical spine. *J Chin Med Assoc* 2009;72(1):48-51.
49. Lyons FA, Rockwood CA Jr: Migration of pins used in operations on the shoulder. *J Bone Joint Surg Am* 1990; 72(8):1262-1267.
50. Anderson K: Evaluation and treatment of distal clavicle fractures. *Clin Sports Med* 2003;22(2):319-326, vii.
51. Heim U, Pfeiffer KM: *Internal Fixation of Small Fractures: Technique Recommended by the AO-ASIF Group*, ed 3. New York, NY, Springer-Verlag, 1987.
52. Kao FC, Chao EK, Chen CH, Yu SW, Chen CY, Yen CY: Treatment of distal clavicle fracture using Kirschner wires and tension-band wires. *J Trauma* 2001; 51(3):522-525.